CASE RECORDS of the MASSACHUSETTS GENERAL HOSPITAL

Founded by Richard C. Cabot
Eric S. Rosenberg, M.D., *Editor*
David M. Dudzinski, M.D., Meridale V. Baggett, M.D., Daniel Restrepo, M.D.,
Dennis C. Sgroi, M.D., Jo-Anne O. Shepard, M.D., *Associate Editors*, Emily K. McDonald, *Production Editor*

# Case 4-2026: An 80-Year-Old Woman with Cough and Hypoxemia

Shreya Shrestha, M.D., M.P.H.,[1,2] Tyler Brown, M.D.,[3,4] Jacqueline T. Chu, M.D.,[1,2] and M. Lauren Donnelly-Morell, M.D., Ph.D.[5,6]

Author affiliations are listed at the end of the article.

N Engl J Med 2026;394:498-507.
DOI: 10.1056/NEJMcpc2513543
*Copyright © 2026 Massachusetts Medical Society.*

CME

## PRESENTATION OF CASE

*Dr. Linda M. Morris* (Medicine): An 80-year-old woman was admitted to this hospital because of cough and hypoxemia.

The patient had been in her usual state of health — active in her community and biking to appointments and social engagements — until 8 weeks before the current presentation, when a productive cough developed. She also had rhinorrhea and headache, as well as fatigue and poor appetite. The patient thought that she might have influenza but did not seek medical care. During the next 3 weeks, rhinorrhea and headache resolved, but cough, fatigue, and poor appetite persisted.

Five weeks before the current presentation, the patient presented to her primary care physician with a pruritic, vesicular rash in a dermatomal distribution on the left flank. She also noted subjective chills. She received a diagnosis of herpes zoster, and treatment with valacyclovir was started, along with acetaminophen as needed for pain. One day later, nausea developed and one episode of vomiting occurred; these symptoms were attributed to the use of valacyclovir. The patient completed a 14-day course of valacyclovir, after which nausea resolved, but cough, fatigue, poor appetite, and chills persisted during the next 3 weeks.

Six days before the current presentation, subjective fever developed, and the patient was evaluated in the urgent care clinic affiliated with her primary care physician's office. She reported that she had lost weight during the previous 8 weeks. The temporal temperature was 37.2°C, the blood pressure 122/86 mm Hg, the heart rate 78 beats per minute, the respiratory rate 18 breaths per minute, and the oxygen saturation 94% while she was breathing ambient air. The weight was 57.4 kg and had decreased by 6.1 kg since the last time her weight had been checked in the clinic, 9 months earlier. The lungs were reportedly clear on auscultation. The blood levels of glucose, electrolytes, aspartate aminotransferase, and alanine aminotransferase were normal, as were the results of kidney-function tests; other laboratory test results are shown in Table 1. Chest radiography reportedly showed normal lungs with possible trace fluid in the fissure. A 5-day course of oral doxycycline was prescribed, along with benzonatate, and an appointment was scheduled with the patient's primary care physician for evaluation of weight loss.



The New England Journal of Medicine is produced by NEJM Group, a division of the Massachusetts Medical Society.
Downloaded from nejm.org by TOM HSIUNG on January 30, 2026.
Copyright © 2026 Massachusetts Medical Society. All rights reserved, including those for text and data mining, AI training, and similar technologies.

**Table 1. Laboratory Data.**

| Variable | Reference Range, Adults, Urgent Care Clinic | 6 Days before Current Presentation, Urgent Care Clinic | Reference Range, Adults, This Hospital* | On Current Presentation, This Hospital |
|---|---|---|---|---|
| Hematocrit (%) | 34–47 | 38.5 | 36–46 | 35.3 |
| Hemoglobin (g/dl) | 12–16 | 12.9 | 12–16 | 12.1 |
| White-cell count (per μl) | 4500–11,000 | 5900 | 4000–11,000 | 7810 |
| Differential count (per μl) | | | | |
| Neutrophils | 1800–8000 | 4190 | 1920–7600 | 6230 |
| Lymphocytes | 1000–4800 | 870 | 720–4100 | 740 |
| Monocytes | 220–1000 | 640 | 160–1100 | 690 |
| Eosinophils | 0–600 | 180 | 0–500 | 70 |
| Basophils | 0–300 | 30 | 0–150 | 40 |
| Platelet count (per μl) | 150,000–400,000 | 253,000 | 150,000–450,000 | 296,000 |
| C-reactive protein (mg/liter) | — | — | <8.0 | 52.7 |
| Erythrocyte sedimentation rate (mm/hr) | — | — | 0–29 | 58 |
| Procalcitonin (ng/ml) | — | — | <0.25 | 0.11 |
| Venous blood gas | | | | |
| pH | — | — | 7.30–7.40 | 7.48 |
| Partial pressure of oxygen (mm Hg) | — | — | 35–50 | 49 |
| Partial pressure of carbon dioxide (mm Hg) | — | — | 38–50 | 32 |

* Reference values are affected by many variables, including the patient population and the laboratory methods used. The ranges used at Massachusetts General Hospital are age-adjusted and apply to patients without medical conditions that could affect the results. They may therefore not be appropriate for all patients.

One day after the patient completed the course of doxycycline, shortness of breath developed, and she was evaluated in the emergency department of this hospital. She had no orthopnea or chest pain. Her medical history included allergic rhinitis, anxiety, and chronic kidney disease. One year before the current presentation, the patient had received a diagnosis of metastatic squamous-cell carcinoma of unknown primary site after presenting with a palpable left axillary lymph node. At that time, flow cytometry of the biopsy specimen was performed, but there were insufficient cells for analysis. Combined positron-emission tomography and computed tomography (CT) revealed multiple hypermetabolic lymph nodes in the left cervical chain, as well as a region of hypermetabolism in the left lateral portion of the oropharynx that corresponded with the left tonsillar pillar. The left tonsil was resected but showed no evidence of cancer. The patient underwent lymphadenectomy of the left axillary lymph node with known carcinoma, as well as concurrent dissection of seven additional lymph nodes, which also showed no evidence of cancer.

The patient's current medications included citalopram, loratadine, and fluticasone propionate nasal spray. She had no known adverse reactions to medications. Her family history included hypertension in her mother and maternal grandmother; her father had died from gastric cancer at 53 years of age. The patient was single and lived in Massachusetts; she had no pets. She had been sexually active until 2 years before the current presentation. She had retired from her job at a nonprofit organization, for which she had traveled extensively. She had taken trips to South America, Central America, and East Africa; her most recent travel outside the United States was a trip to Kenya, Rwanda, and Tanzania 6 years before the current presentation. She was a lifelong nonsmoker and did not use illicit drugs. She drank one glass of wine per week.

On examination, the temporal temperature was 37.3°C, the blood pressure 158/86 mm Hg, the pulse 93 beats per minute, the respiratory rate



The New England Journal of Medicine is produced by NEJM Group, a division of the Massachusetts Medical Society.
Downloaded from nejm.org by TOM HSIUNG on January 30, 2026.
Copyright © 2026 Massachusetts Medical Society. All rights reserved, including those for text and data mining, AI training, and similar technologies.

16 breaths per minute, and the oxygen saturation 83% while the patient was breathing ambient air. She was coughing but able to speak in complete sentences without respiratory distress. The oxygen saturation increased to 93% while the patient was receiving supplemental oxygen through a nasal cannula at a rate of 4 liters per minute. The oropharynx was clear. On the pulmonary examination, rhonchi were present over all the lung fields but were most prominent over the right lower lobe. On the cardiac examination, the heart rate and rhythm were regular, without murmurs; no jugular venous distention was noted. There was no clubbing or edema. The remainder of the examination was normal.

The blood levels of glucose, electrolytes, aspartate aminotransferase, and alanine aminotransferase were normal, as were the results of kidney-function tests. The blood level of N-terminal pro–B-type natriuretic peptide was 704 pg per milliliter (reference range, 0 to 1800); other laboratory test results are shown in Table 1. Testing for severe acute respiratory syndrome coronavirus 2 (SARS-CoV-2), influenza virus, and respiratory syncytial virus was negative, as was an extended respiratory viral panel. Testing for *Bordetella pertussis*, *B. parapertussis*, *Chlamydia pneumoniae*, and *Mycoplasma pneumoniae* was also negative.

*Dr. Tyler Brown:* On admission, chest radiography (Fig. 1A) revealed hazy perihilar opacities with

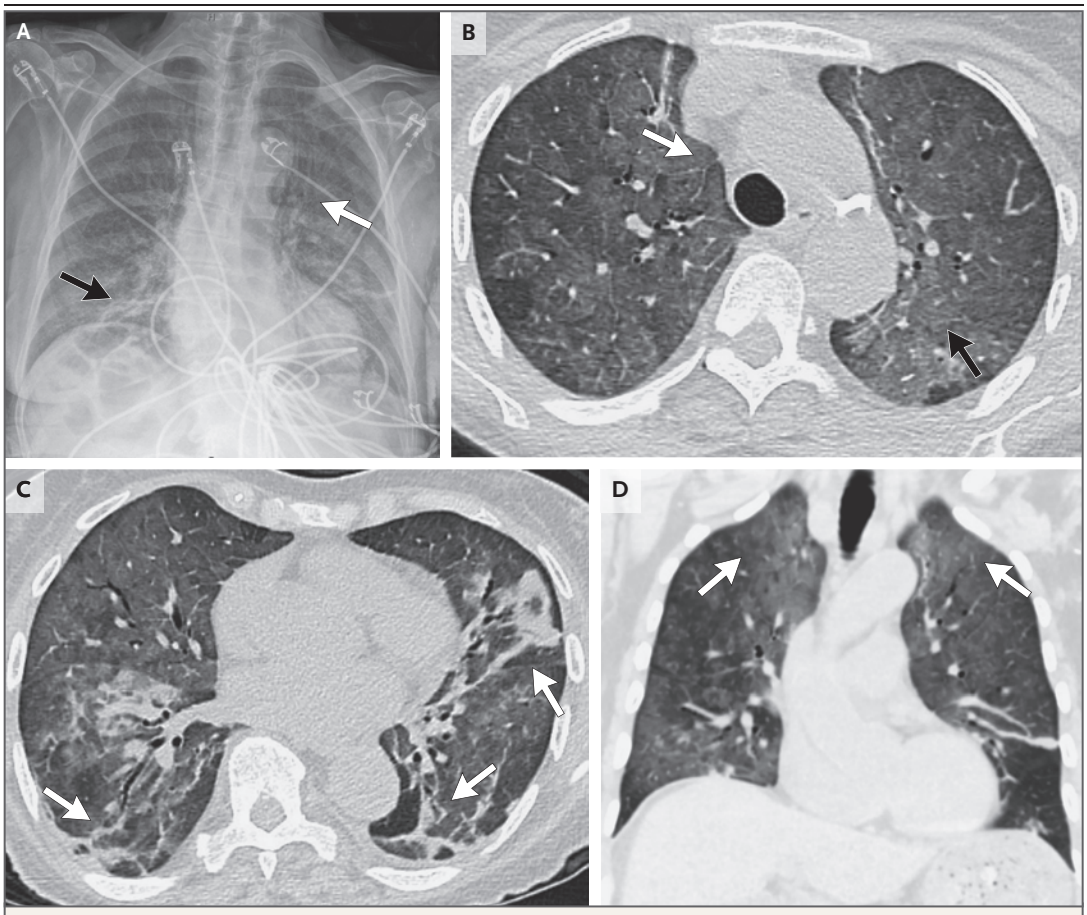


**Figure 1. Chest Imaging Studies.**
A frontal chest radiograph (Panel A) shows hazy perihilar opacities with indistinct vasculature (white arrow) and linear opacities at the lung bases that are most likely indicative of subsegmental atelectasis (black arrow). An axial CT image at the lung apices (Panel B) shows diffuse ground-glass opacities (white arrow) and trace interlobular septal thickening (black arrow). An axial CT image at the lung bases (Panel C) shows patchy atelectasis in both lungs (arrows). A coronal CT image (Panel D) shows central (rather than peripheral) ground-glass opacities with apical predominance (arrows).



The New England Journal of Medicine is produced by NEJM Group, a division of the Massachusetts Medical Society.
Downloaded from nejm.org by TOM HSIUNG on January 30, 2026.
Copyright © 2026 Massachusetts Medical Society. All rights reserved, including those for text and data mining, AI training, and similar technologies.

indistinct pulmonary vasculature, as well as linear opacities at the lung bases that were most likely indicative of subsegmental atelectasis. The cardiac silhouette was normal, and there was no pleural effusion. Subsequent chest CT (Fig. 1B, 1C, and 1D) revealed diffuse central (rather than peripheral) ground-glass opacities in both lungs with apical predominance, sparing the lung bases. Trace interlobular septal thickening was present; however, there was no pleural effusion, and the cardiac chambers were normal in size. No evidence of pulmonary nodules, cysts, or bronchiectasis was identified, and no lymphadenopathy was present.

*Dr. Morris:* Treatment with intravenous ceftriaxone and oral azithromycin was started. On hospital day 2, the temporal temperature increased to 39.3°C. The blood pressure was 151/79 mm Hg, the heart rate 108 beats per minute, the respiratory rate 16 breaths per minute, and the oxygen saturation 92% while the patient was receiving supplemental oxygen through a nasal cannula at a rate of 4 liters per minute. Blood specimens were obtained for culture.

A diagnostic test was performed.

## DIFFERENTIAL DIAGNOSIS

*Dr. Shreya Shrestha:* This older woman had been in relatively good health until 8 weeks before the current presentation, when cough, fatigue, anorexia, and weight loss developed. She presented with shortness of breath and was found to be febrile and hypoxemic, with diffuse ground-glass opacities seen on chest CT. Given the undifferentiated nature of the patient's subacute respiratory syndrome, I will begin by considering broad categories of disease, including infection, cancer, and autoimmune and connective-tissue disorders.

### INFECTION

In this febrile and hypoxemic patient with involvement of the lower respiratory tract, bacterial infection should be considered. However, the progression of symptoms over a period of 8 weeks is uncharacteristic of typical bacterial pneumonia. Atypical pneumonia could be considered, but initial laboratory testing was negative for *C. pneumoniae* and *M. pneumoniae*, and the lack of improvement after a 5-day course of doxycycline (before admission) and the worsening symptoms despite treatment with azithromycin (after admission) are inconsistent with this diagnosis. It is notable that the level of procalcitonin, a serum biomarker that is often elevated in patients with bacterial infections but not in those with other infectious or inflammatory diseases, was not elevated in this patient.[1]

Viral infection is also a consideration in this patient. Laboratory testing performed on presentation was negative for SARS-CoV-2, influenza virus, and respiratory syncytial virus, and an extended respiratory viral panel was also negative. The recent diagnosis of herpes zoster suggests the possibility of disseminated varicella–zoster virus (VZV) infection that had led to pneumonia, a rare complication.[2] However, dissemination of VZV typically occurs within a week after the development of cutaneous herpes zoster,[3] whereas shortness of breath occurred 5 weeks after the diagnosis of herpes zoster in this patient. In addition, VZV pneumonitis is characterized by diffuse or patchy nodular opacities on imaging; ground-glass opacities, if present, tend to be associated with nodular findings.[4]

### CANCER

Approximately 1 year before the current presentation, the patient had received a diagnosis of metastatic squamous-cell carcinoma of unknown primary site with involvement of a left axillary lymph node. This aspect of her medical history suggests the possibility of recurrent or metastatic cancer; however, she had undergone lymphadenectomy of the node with known carcinoma, and there was no evidence of residual disease. Other possibilities include a primary or secondary lymphoproliferative disorder or lymphangitic spread of a different cancer. Cancer with pulmonary involvement can result in bronchovascular thickening, pleural effusion, or hilar or mediastinal lymphadenopathy. Lymphoma with pulmonary involvement most commonly manifests as a mass or masslike consolidation,[5] whereas lymphangitic carcinomatosis with pulmonary involvement tends to manifest as nodular or irregular septal thickening.[6] The findings on chest CT in this patient are not compatible with any of these diagnoses.

### AUTOIMMUNE AND CONNECTIVE-TISSUE DISORDERS

Autoimmune disorders merit consideration, given the patient's constitutional symptoms, elevated levels of inflammatory markers, and diffuse ground-glass opacities on chest CT. Antineutrophil cytoplasmic antibody (ANCA)–associated vascu-



The New England Journal of Medicine is produced by NEJM Group, a division of the Massachusetts Medical Society.
Downloaded from nejm.org by TOM HSIUNG on January 30, 2026.
Copyright © 2026 Massachusetts Medical Society. All rights reserved, including those for text and data mining, AI training, and similar technologies.

litides, specifically granulomatosis with polyangiitis and microscopic polyangiitis, may result in ground-glass opacities due to pulmonary hemorrhage. These small-vessel vasculitides often involve multiple organ systems and may cause glomerulonephritis, neuropathy, and purpura. Granulomatosis with polyangiitis, in particular, may also affect the upper airway.[7] The third type of ANCA-associated vasculitis, eosinophilic granulomatosis with polyangiitis, classically causes rhinosinusitis, asthma, and eosinophilia, along with nasal polyps, peripheral neuropathy, and skin nodules.[8] This patient had a history of allergic rhinitis but did not have evidence of refractory symptoms or a lack of response to nasal glucocorticoid treatment. In addition, the absence of multisystem involvement would be atypical for any of these diagnoses.

Connective-tissue disorders tend to manifest similarly, with multisystem involvement and an array of imaging features, including pleural and pericardial effusions (in the case of systemic lupus erythematosus), pulmonary fibrosis (in systemic sclerosis, dermatomyositis, or Sjögren's syndrome), bronchiectasis, or honeycombing. Ground-glass opacities can also be seen; for instance, they may be due to inflammation from acute lupus pneumonitis or alveolar hemorrhage.

Overall, the absence of multisystem involvement would be atypical for both autoimmune and connective-tissue disorders. I will continue to seek a more compelling hypothesis.

### IMMUNOCOMPROMISED HOST

The patient had a relatively slow progression of symptoms, over a period of 8 weeks, that eventually culminated in a more acute presentation with fever, hypoxemia, and diffuse ground-glass opacities. The clinical course merits consideration of atypical diseases, including those that may be associated with immunocompromise. Although herpes zoster is commonly associated with advanced age,[9] it may also indicate an underlying immunodeficiency syndrome.

Pivoting into this theory requires revisiting this patient's clinical timeline, not just in the past several weeks but in the past decade. The patient had a history of extensive international travel, including trips to East Africa, Central America, and South America. Her last trip had been approximately 6 years earlier, and she had visited Kenya, Rwanda, and Tanzania. She had been sexually active until 2 years before the current presentation, which suggests the possibility that she had acquired human immunodeficiency virus (HIV) infection during her travels to regions of East Africa where the disease is endemic and the prevalence of the virus is higher than the global average.[10]

After a relatively quiescent clinical phase in which the CD4 cell count declines, persons with HIV infection are susceptible to an array of opportunistic infections.[11] These include, but are not limited to, tuberculosis and reactivation of VZV infection (at any CD4 cell count), coccidioidomycosis (CD4 cell count, ≤250 per microliter), *Pneumocystis jirovecii* pneumonia (CD4 cell count, ≤200 per microliter), histoplasmosis (CD4 cell count, ≤150 per microliter), cryptococcus and cytomegalovirus infections (CD4 cell count, ≤100 per microliter), and *Mycobacterium avium* complex infection (CD4 cell count, ≤50 per microliter).

Primary tuberculosis or reactivation of tuberculosis may have an atypical presentation, especially in immunocompromised patients. However, the pulmonary findings on imaging in this patient are not characteristic of either primary tuberculosis (which typically manifests with lower- and middle-lobe consolidations, intrathoracic lymphadenopathy, and pleural effusion) or tuberculosis reactivation (which most often manifests with upper-lobe consolidations, cavitating lesions, bronchiectasis, and endobronchial spread).[12]

Endemic mycoses — including histoplasmosis, coccidioidomycosis, and paracoccidioidomycosis — are also a possibility, given the patient's symptoms and history of travel to Central America and South America, where these infections are prevalent. However, the characteristic features of these fungal pneumonias on chest CT include focal opacities, mediastinal or hilar lymphadenopathy, and diffuse reticulonodular opacities in cases associated with extensive exposure, and none of these findings were present in this patient.[13,14]

Among the opportunistic infections that are related to HIV infection, *P. jirovecii* pneumonia is one of the most common and was one of the first reported acquired immunodeficiency syndrome (AIDS)–defining illnesses.[15,16] Patients with *P. jirovecii* pneumonia present with cough, dyspnea, and fever over the course of days to weeks, and they can also present with weight loss and anorexia. Characteristic features on chest CT include ground-glass opacities in both lungs, which are present in the majority of persons living with



The New England Journal of Medicine is produced by NEJM Group, a division of the Massachusetts Medical Society.
Downloaded from nejm.org by TOM HSIUNG on January 30, 2026.
Copyright © 2026 Massachusetts Medical Society. All rights reserved, including those for text and data mining, AI training, and similar technologies.

HIV infection who have *P. jirovecii* pneumonia.[17] Patchy consolidation and interlobular septal thickening can also be present, and these findings were also seen in this case.

Given the clinical timeline, risk factors, symptom burden, and imaging findings in this case, the most likely underlying explanation for the patient's systemic and respiratory syndrome is HIV–AIDS complicated by *P. jirovecii* pneumonia. This patient is older than the typical patient with a new onset of HIV infection, but when risk factors are present — such as travel and sexual history — testing is imperative. The recent diagnosis of herpes zoster, which can be an immunodeficiency-related syndrome, is likely to be another major clue.

To confirm the diagnosis, I would perform serologic testing for HIV-1. Given the possibility of *P. jirovecii* pneumonia, I would perform a direct fluorescent antibody test for *P. jirovecii* on an induced sputum specimen. If the test is negative, I would perform a direct fluorescent antibody test on a bronchoalveolar-lavage (BAL) specimen. The serum level of 1,3-$\beta$-D-glucan, which is typically elevated in patients with *P. jirovecii* pneumonia, could also be obtained.

## DR. SHREYA SHRESTHA'S DIAGNOSIS

Advanced human immunodeficiency virus infection complicated by *Pneumocystis jirovecii* pneumonia.

## CLINICAL IMPRESSION

*Dr. Stephanie Cabral* (Medicine): When the pulmonary consulting team evaluated this patient, we considered both infectious and inflammatory conditions. We recommended empirical treatment for community-acquired pneumonia, as well as testing for HIV infection and ANCA-associated vasculitis.

## DIAGNOSTIC TESTING

*Dr. M. Lauren Donnelly-Morell:* The first diagnostic test performed in this case was an antigen–antibody combination immunoassay for HIV-1 and HIV-2, which was reactive. Confirmatory and differentiation testing was positive for HIV-1. The plasma HIV-1 viral load was 223,000 copies of RNA per milliliter, and the CD4 cell count was 33 per microliter, findings that established the diagnosis of advanced HIV-1 infection.

Gram's staining of induced sputum showed no polymorphonuclear leukocytes, rare squamous epithelial cells, and no organisms. A direct fluorescent antibody test for *P. jirovecii* in the induced sputum was negative. However, a serum test for 1,3-$\beta$-D-glucan was strongly positive (>500 pg per milliliter; reference value, <60), a finding that increased suspicion for *P. jirovecii* pneumonia. Because of the high pretest probability of this diagnosis, BAL was performed, and a direct fluorescent antibody test of the fluid for *P. jirovecii* was positive (Fig. 2).

*P. jirovecii* was originally classified as a protozoan but is now recognized as an ascomycetous fungus. The organism does not grow on routine mycology media; therefore, immunofluorescence assays, such as the direct fluorescent antibody test, remain the standard diagnostic approach.[18] The specificity of direct fluorescent antibody testing is greater than 99%, whereas the sensitivity depends on the specimen type and host immune status. With induced sputum, the sensitivity ranges from 67 to 99% in persons with HIV infection but is less than 50% in immunocompetent hosts. BAL fluid analysis provides superior diagnostic yield, with a sensitivity of 90 to 99% in persons with HIV infection.[19,20] Nucleic acid amplification assays have even greater sensitivity, but interpretation of the results can be difficult; pneumocystis DNA may be detected in colonized but asymptomatic hosts, which makes it challenging to distinguish actual infection from colonization.

Unexpectedly, on hospital day 3, yeast colonies grew in a fungal culture of the BAL fluid. The colonies were cream-colored, smooth, and mucoid and were identified as *Cryptococcus neoformans.* Two serum cryptococcal antigen tests were negative. These results are not considered to be inconsistent with the culture finding, since cryptococcal antigen testing is most sensitive for disseminated or central nervous system (CNS) disease and may be negative in cases of isolated pulmonary infection when the fungal burden is low.[21]

## LABORATORY DIAGNOSIS

Advanced human immunodeficiency virus type 1 infection, *Pneumocystis jirovecii* pneumonia, and *Cryptococcus neoformans* pneumonia.



The New England Journal of Medicine is produced by NEJM Group, a division of the Massachusetts Medical Society.
Downloaded from nejm.org by TOM HSIUNG on January 30, 2026.
Copyright © 2026 Massachusetts Medical Society. All rights reserved, including those for text and data mining, AI training, and similar technologies.

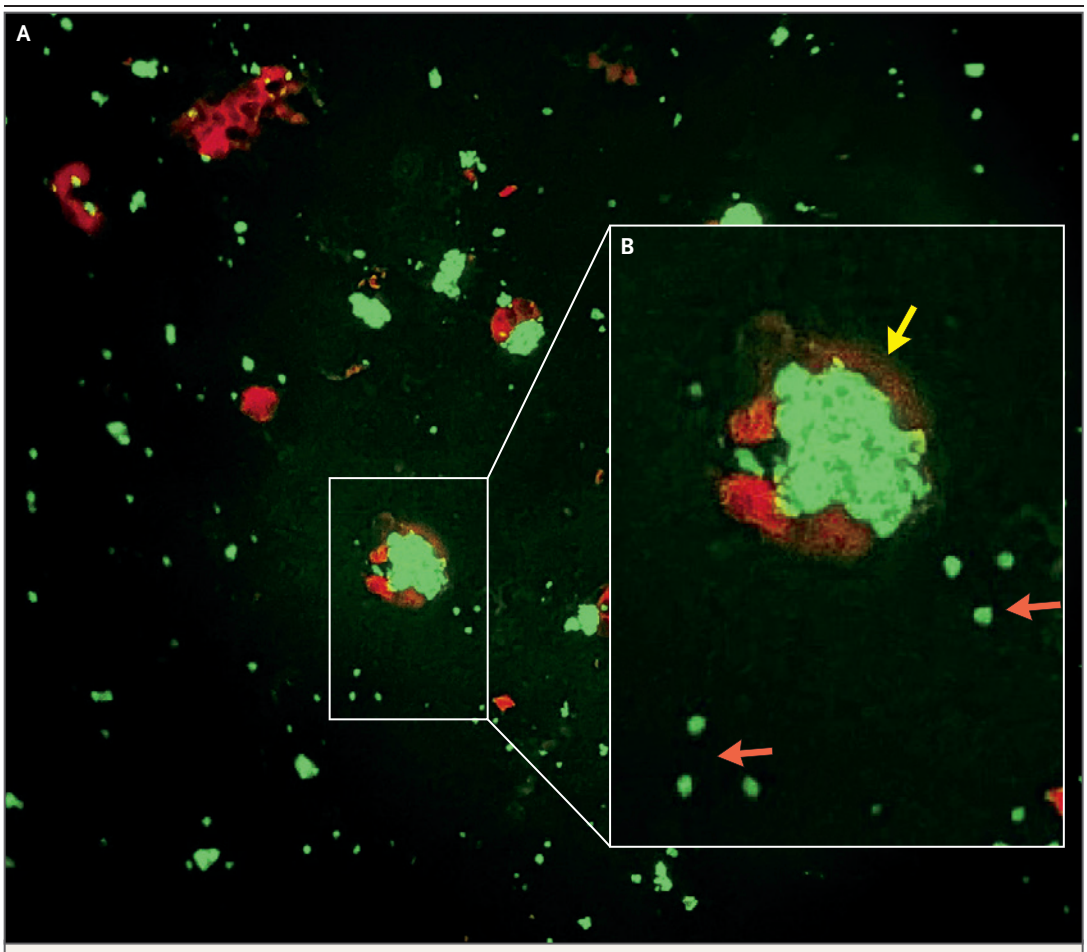


**Figure 2. Bronchoalveolar-Lavage Specimen.**

Panel A shows *Pneumocystis jirovecii* organisms (in green), including trophozoites and cysts, detected by monoclonal antibodies conjugated with fluorescein isothiocyanate, or FITC (MONOFLUO *P. jirovecii* immunofluorescence assay). Cellular material is counterstained with Evans blue (in red). Panel B shows individual cysts (red arrows) and clusters of round cyst forms embedded within the extracellular matrix (yellow arrow) at higher magnification.

## DISCUSSION OF MANAGEMENT

*Dr. Jacqueline T. Chu:* In severely immunocompromised hosts, *P. jirovecii* causes predominantly respiratory disease. A report that described 5 cases of biopsy-confirmed *P. jirovecii* pneumonia occurring in previously healthy young men from 1980 to 1981[22] and two subsequent reports published in the *Journal* that described a total of 15 additional cases[23,24] became the harbinger of the HIV–AIDS epidemic.

*P. jirovecii* pneumonia remains one of the leading opportunistic infections among persons living with advanced HIV infection, especially those with previously undiagnosed HIV infection. This patient had a subacute presentation over a period of several weeks, with gradual decline punctuated by dyspnea on exertion and ultimately marked hypoxemia — hallmark features of *P. jirovecii* pneumonia.

After serologic testing for HIV was positive, treatment for presumptive *P. jirovecii* pneumonia was initiated. Treatment of *P. jirovecii* pneumonia involves the selection of antimicrobial agents, as well as consideration of adjunctive glucocorticoid therapy for patients with more severe disease. First-line treatment with high-dose trimethoprim–sulfamethoxazole is strongly preferred over next-line agents owing to superior efficacy, even though the high dose warrants close monitoring of po-



The New England Journal of Medicine is produced by NEJM Group, a division of the Massachusetts Medical Society.
Downloaded from nejm.org by TOM HSIUNG on January 30, 2026.
Copyright © 2026 Massachusetts Medical Society. All rights reserved, including those for text and data mining, AI training, and similar technologies.

tassium levels and kidney function.[25-27] Adjunctive glucocorticoid therapy may be administered to attenuate inflammation resulting from the immune response to pneumocystis activity and to dying organisms in this highly inflammatory state. Glucocorticoid therapy is indicated for patients with moderate-to-severe *P. jirovecii* pneumonia, which is defined by a partial pressure of arterial oxygen of less than 70 mm Hg while the patient is breathing ambient air or by an alveolar–arterial gradient of 35 mm Hg or higher.[28,29] Because this patient had clinically significant hypoxemia while she was breathing ambient air, an arterial blood gas analysis was unnecessary; her oxygen saturation was correlated with an adequately severe degree of illness to warrant the initiation of prednisone therapy.

The discovery of *C. neoformans* growth in the BAL fluid culture was unexpected but not surprising, given that a low CD4 cell count confers a predisposition to the development of multiple concurrent opportunistic infections. The negative serum cryptococcal antigen tests indicated that the patient had localized disease. A lumbar puncture was performed for analysis of the cerebrospinal fluid (CSF), which ruled out CNS disease,[30,31] and treatment with fluconazole was initiated.[32]

For the initiation of antiretroviral therapy (ART) in this patient, there were multiple important timing considerations. Persons with a new diagnosis of HIV infection who are treated early have fewer AIDS-defining diseases and a lower risk of death (including lower mortality among those with *P. jirovecii* pneumonia) than persons who are treated later[30,31]; early treatment also leads to greater viral suppression and patient retention in care.[33-35] However, multiple studies in sub-Saharan Africa have shown increases in morbidity and mortality after early initiation of ART among patients with cryptococcal meningitis,[36,37] and guidelines recommend delaying the start of ART in such patients. Given that CSF analysis had ruled out cryptococcal meningitis in this patient, treatment with bictegravir–emtricitabine–tenofovir alafenamide was started.

The patient had a favorable response to treatment, with a marked decrease in symptoms and increase in oxygenation after the initiation of antimicrobial and glucocorticoid therapy. She had an acceptable side-effect profile with ART; however, she faced a high copay for her medications, paying $700 for her first month of treatment after discharge. She was subsequently enrolled in the AIDS Drug Assistance Program, which has since helped cover her monthly copays.[38,39] This funding is an essential stopgap for many persons with HIV infection; in 2023, more than 50% of those who received a diagnosis of HIV infection in the United States had support through medication assistance or care coordination from the federally funded Ryan White HIV/AIDS Program. Known as a payer of last resort, this program closes gaps for qualifying patients who cannot afford medications, ensuring durable viral suppression that can lead to reductions in mortality and spread of the virus.[40] The Ryan White HIV/AIDS Program is the third largest funder of HIV care in the United States, with Medicare and Medicaid being the two largest, and when Medicaid eligibility is cut, more patients will turn to discretionary funds, which have unclear budget allocations. Given the importance of durable viral suppression, HIV care providers must pay close attention to policy changes to ensure that their patients have continuous access to these lifesaving medications.

This patient had frequent follow-up visits with both her primary care physician and her infectious diseases physician. She had complete resolution of shortness of breath, with slower resolution of fatigue. After she completed a 3-week course of high-dose trimethoprim–sulfamethoxazole, the dose was reduced to a level appropriate for prophylaxis. Treatment with fluconazole was continued for a total of 6 months. The patient's HIV viral load quickly became undetectable, and her care teams have shifted their focus toward HIV-informed health maintenance topics. She is currently dating, fortified with the knowledge that "U = U: undetectable = untransmissible."

This case underscores the importance of assessing risk factors to inform the screening strategy for HIV infection and sexually transmitted infections in older adults. In 2021, in the United States, 41% of persons living with HIV infection were 55 years of age or older.[41] Among those who received the diagnosis when they were 55 years of age or older, 34% received a diagnosis of AIDS. Screening for HIV infection occurs less frequently in older adults than in younger persons,



The New England Journal of Medicine is produced by NEJM Group, a division of the Massachusetts Medical Society.
Downloaded from nejm.org by TOM HSIUNG on January 30, 2026.
Copyright © 2026 Massachusetts Medical Society. All rights reserved, including those for text and data mining, AI training, and similar technologies.

perhaps because of the broad range of other topics to cover during appointments, social norms in this age group, the potential for embarrassment, and assumptions that may be held by some clinicians about sexual activity in older adults.[42,43] Patients are more likely than clinicians to initiate conversations about sexual health. Clinicians can employ one of many frameworks for the initiation of discussions about sexual health.[44] The Centers for Disease Control and Prevention recommends asking about the "five Ps": partners, practices, protection (prevention of sexually transmitted infections), past (history of sexually transmitted infections), and pregnancy intention. On the basis of the risk assessment in this patient, regular screening would be recommended.

## FINAL DIAGNOSIS

*Pneumocystis jirovecii* pneumonia and cryptococcal pneumonia in the context of advanced human immunodeficiency virus type 1 infection.

This case was presented at the Medicine Case Conference.

Disclosure forms provided by the authors are available with the full text of this article at NEJM.org.

We thank Amita Sharma and John Branda for review of the radiology and pathology portions of this manuscript, respectively.

**AUTHOR INFORMATION**

[1]Department of Medicine, Massachusetts General Hospital, Boston; [2]Department of Medicine, Harvard Medical School, Boston; [3]Department of Radiology, Massachusetts General Hospital, Boston; [4]Department of Radiology, Harvard Medical School, Boston; [5]Department of Pathology, Massachusetts General Hospital, Boston; [6]Department of Pathology, Harvard Medical School, Boston.

**REFERENCES**

**1.** Self WH, Balk RA, Grijalva CG, et al. Procalcitonin as a marker of etiology in adults hospitalized with community-acquired pneumonia. Clin Infect Dis 2017;65:183-90.

**2.** Schlossberg D, Littman M. Varicella pneumonia. Arch Intern Med 1988;148:1630-2.

**3.** Mohsen AH, McKendrick M. Varicella pneumonia in adults. Eur Respir J 2003;21:886-91.

**4.** Kim JS, Ryu CW, Lee SI, Sung DW, Park CK. High-resolution CT findings of varicella-zoster pneumonia. AJR Am J Roentgenol 1999;172:113-6.

**5.** Lewis ER, Caskey CI, Fishman EK. Lymphoma of the lung: CT findings in 31 patients. AJR Am J Roentgenol 1991;156:711-4.

**6.** Johkoh T, Ikezoe J, Tomiyama N, et al. CT findings in lymphangitic carcinomatosis of the lung: correlation with histologic findings and pulmonary function tests. AJR Am J Roentgenol 1992;158:1217-22.

**7.** Jennette JC, Falk RJ. Small-vessel vasculitis. N Engl J Med 1997;337:1512-23.

**8.** Cottin V, Bel E, Bottero P, et al. Revisiting the systemic vasculitis in eosinophilic granulomatosis with polyangiitis (Churg-Strauss): a study of 157 patients by the Groupe d'Etudes et de Recherche sur les Maladies Orphelines Pulmonaires and the European Respiratory Society Taskforce on eosinophilic granulomatosis with polyangiitis (Churg-Strauss). Autoimmun Rev 2017;16:1-9.

**9.** Yawn BP, Saddier P, Wollan PC, St Sauver JL, Kurland MJ, Sy LS. A population-based study of the incidence and complication rates of herpes zoster before zoster vaccine introduction. Mayo Clin Proc 2007;82:1341-9.

**10.** The Joint United Nations Programme on HIV/AIDS. Communities at the centre: defending rights, breaking barriers, reaching people with HIV services. Global AIDS Update. 2019 (https://www.unaids.org/sites/default/files/media_asset/2019-global-AIDS-update_en.pdf).

**11.** Enger C, Graham N, Peng Y, et al. Survival from early, intermediate, and late stages of HIV infection. JAMA 1996;275:1329-34.

**12.** Barnes PF, Verdegem TD, Vachon LA, Leedom JM, Overturf GD. Chest roentgenogram in pulmonary tuberculosis: new data on an old test. Chest 1988;94:316-20.

**13.** Meals LT, McKinney WP. Acute pulmonary histoplasmosis: progressive pneumonia resulting from high inoculum exposure. J Ky Med Assoc 1998;96:258-60.

**14.** Peterson MW, Jain R, Hildebrandt K, Carson WK, Fayed MA. Differentiating lung nodules due to *Coccidioides* from those due to lung cancer based on radiographic appearance. J Fungi (Basel) 2023;9:641.

**15.** Huang L, Cattamanchi A, Davis JL, et al. HIV-associated Pneumocystis pneumonia. Proc Am Thorac Soc 2011;8:294-300.

**16.** Tasaka S. Pneumocystis pneumonia in human immunodeficiency virus-infected adults and adolescents: current concepts and future directions. Clin Med Insights Circ Respir Pulm Med 2015;9:Suppl 1:19-28.

**17.** Kanne JP, Yandow DR, Meyer CA. *Pneumocystis jiroveci* pneumonia: high-resolution CT findings in patients with and without HIV infection. AJR Am J Roentgenol 2012;198:W555-W561.

**18.** Jaramillo Cartagena A, Asowata OE, Ng D, Babady NE. An overview of the laboratory diagnosis of *Pneumocystis jirovecii* pneumonia. J Clin Microbiol 2025;63(3):e0036124.

**19.** Bateman M, Oladele R, Kolls JK. Diagnosing *Pneumocystis jirovecii* pneumonia: a review of current methods and novel approaches. Med Mycol 2020;58:1015-28.

**20.** Senécal J, Smyth E, Del Corpo O, et al. Non-invasive diagnosis of *Pneumocystis jirovecii* pneumonia: a systematic review and meta-analysis. Clin Microbiol Infect 2022;28:23-30.

**21.** Perfect JR, Dismukes WE, Dromer F, et al. Clinical practice guidelines for the management of cryptococcal disease: 2010 update by the Infectious Diseases Society ff America. Clin Infect Dis 2010;50:291-322.

**22.** Pneumocystis pneumonia — Los Angeles. MMWR Morb Mortal Wkly Rep 1981;30:250-2 (https://www.cdc.gov/mmwr/preview/mmwrhtml/lmrk077.htm).

**23.** Masur H, Michelis MA, Greene JB, et al. An outbreak of community-acquired *Pneumocystis carinii* pneumonia — initial manifestation of cellular immune dysfunction. N Engl J Med 1981;305:1431-8.

**24.** Gottlieb MS, Schroff R, Schanker HM, et al. *Pneumocystis carinii* pneumonia and mucosal candidiasis in previously healthy homosexual men — evidence of a new acquired cellular immunodeficiency. N Engl J Med 1981;305:1425-31.

**25.** Hughes W, Leoung G, Kramer F, et al. Comparison of atovaquone (566C80) with trimethoprim-sulfamethoxazole to treat *Pneumocystis carinii* pneumonia in patients with AIDS. N Engl J Med 1993;328:1521-7.

**26.** Sattler FR, Cowan R, Nielsen DM, Ruskin J. Trimethoprim-sulfamethoxazole compared with pentamidine for treatment of *Pneumocystis carinii* pneumonia in the acquired immunodeficiency syndrome: a prospective, noncrossover study. Ann Intern Med 1988;109:280-7.

**27.** Butler-Laporte G, Smyth E, Amar-



The New England Journal of Medicine is produced by NEJM Group, a division of the Massachusetts Medical Society.
Downloaded from nejm.org by TOM HSIUNG on January 30, 2026.
Copyright © 2026 Massachusetts Medical Society. All rights reserved, including those for text and data mining, AI training, and similar technologies.

Zifkin A, Cheng MP, McDonald EG, Lee TC. Low-dose TMP-SMX in the treatment of *Pneumocystis jirovecii* pneumonia: a systematic review and meta-analysis. Open Forum Infect Dis 2020;7(5):ofaa112.
**28.** Bozzette SA, Sattler FR, Chiu J, et al. A controlled trial of early adjunctive treatment with corticosteroids for *Pneumocystis carinii* pneumonia in the acquired immunodeficiency syndrome. N Engl J Med 1990;323:1451-7.
**29.** Briel M, Bucher HC, Boscacci R, Furrer H. Adjunctive corticosteroids for Pneumocystis jiroveci pneumonia in patients with HIV-infection. Cochrane Database Syst Rev 2006;3:CD006150.
**30.** Manzardo C, Esteve A, Ortega N, et al. Optimal timing for initiation of highly active antiretroviral therapy in treatment-naïve human immunodeficiency virus-1-infected individuals presenting with AIDS-defining diseases: the experience of the PISCIS Cohort. Clin Microbiol Infect 2013;19:646-53.
**31.** Zolopa A, Andersen J, Powderly W, et al. Early antiretroviral therapy reduces AIDS progression/death in individuals with acute opportunistic infections: a multicenter randomized strategy trial. PLoS One 2009;4(5):e5575.
**32.** Chang CC, Harrison TS, Bicanic TA, et al. Global guideline for the diagnosis and management of cryptococcosis: an initiative of the ECMM and ISHAM in cooperation with the ASM. Lancet Infect Dis 2024;24(8):e495-e512.
**33.** Pilcher CD, Ospina-Norvell C, Dasgupta A, et al. The effect of same-day observed initiation of antiretroviral therapy on HIV viral load and treatment outcomes in a US public health setting. J Acquir Immune Defic Syndr 2017;74:44-51.
**34.** Koenig SP, Dorvil N, Dévieux JG, et al. Same-day HIV testing with initiation of antiretroviral therapy versus standard care for persons living with HIV: a randomized unblinded trial. PLoS Med 2017; 14(7):e1002357.
**35.** Rosen S, Maskew M, Fox MP, et al. Initiating antiretroviral therapy for HIV at a patient's first clinic visit: the RapIT randomized controlled trial. PLoS Med 2016; 13(5):e1002015.
**36.** Boulware DR, Meya DB, Muzoora C, et al. Timing of antiretroviral therapy after diagnosis of cryptococcal meningitis. N Engl J Med 2014;370:2487-98.
**37.** Scriven JE, Rhein J, Hullsiek KH, et al. Early ART after cryptococcal meningitis is associated with cerebrospinal fluid pleocytosis and macrophage activation in a multisite randomized trial. J Infect Dis 2015; 212:769-78.
**38.** KFF. The Ryan White HIV/AIDS Program: the basics. May 29, 2025 (https://www.kff.org/hiv-aids/the-ryan-white-hiv-aids-program-the-basics/).
**39.** Health Resources and Services Administration. AIDS Drug Assistance Program (ADAP). Ryan White HIV/AIDS Program part B (https://ryanwhite.hrsa.gov/about/parts-and-initiatives/part-b-adap).
**40.** Ryan White HIV/AIDS Program achieves record-breaking 90.6% viral suppression rate among its more than 576,000 clients. Press release of the Health Resources and Services Administration, Rockville, MD, December 2, 2024 (https://www.hrsa.gov/about/news/press-releases/ryan-white-record-breaking-viral-suppression-rate).
**41.** HIV surveillance report, 2021. Vol. 34. Atlanta: Centers for Disease Control and Prevention, May 2023.
**42.** Agochukwu-Mmonu N, Malani PN, Wittmann D, et al. Interest in sex and conversations about sexual health with health care providers among older U.S. adults. Clin Gerontol 2021;44:299-306.
**43.** Lubell J. With STIs on rise among older adults, here's what doctors can do. Chicago: American Medical Association, January 6, 2025 (https://www.ama-assn.org/public-health/population-health/stis-rise-among-older-adults-here-s-what-doctors-can-do).
**44.** Centers for Disease Control and Prevention. Guide to taking a sexual history. Sexually transmitted infections (STIs). June 26, 2024 (https://www.cdc.gov/sti/hcp/clinical-guidance/taking-a-sexual-history.html).
*Copyright © 2026 Massachusetts Medical Society.*



The New England Journal of Medicine is produced by NEJM Group, a division of the Massachusetts Medical Society.
Downloaded from nejm.org by TOM HSIUNG on January 30, 2026.
Copyright © 2026 Massachusetts Medical Society. All rights reserved, including those for text and data mining, AI training, and similar technologies.